

The Mandibular Two-Implant Overdenture

First-Choice
Standard of
Care for the
Edentulous
Denture Patient

Joseph R. Carpentieri, DDS
Dennis P. Tarnow, DDS

Preface

The prosthetic management of the edentulous patient has long been a major challenge for dentistry. For well over a century, complete maxillary and mandibular dentures have been the traditional standard of care. However, most patients report significantly more problems adapting to their mandibular denture due to a lack of comfort (eg, they suffer from an increase in pain and soreness), retention, stability, and to the inability to chew and eat. Recent scientific studies carried out over the past decade have determined that the benefits of a mandibular two-implant overdenture are sufficient to propose the two-implant overdenture—rather than the conventional denture—as the first treatment option. This trend in the prosthodontic literature has led to a significant shift in therapeutic philosophy regarding restoration of the edentulous patient.

This brings up the question, what is a standard of care? It is described as an outline of procedures followed in providing care that meets therapeutic goals and minimizes risks and complications, based on the current state of knowledge. The McGill Consensus Statement on the two-implant overdenture is based on a change in the current state of knowledge and was developed by a panel of expert clinicians and scientists who presented information in a symposium focused on overdentures.^{i,ii} This statement indicates that as a minimal treatment objective, the mandibular two-implant overdenture (as opposed to a conventional denture) should be considered as a first-choice standard of care for the edentulous patient.^{i,ii}

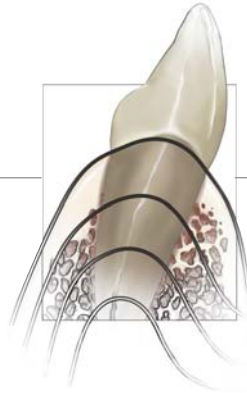
It is important to understand that the conventional complete denture, the two-implant overdenture, multiple-implant splinted or unsplinted overdenture, and fixed implant prostheses are all currently accepted standard-of-care treatments for the edentulous mandible. The McGill Consensus Statement does not preclude more sophisticated treatments (eg, bar overdentures, fixed prostheses). It states “as a minimal treatment objective,” meaning the authors, through their own extensive review of the literature, would like to further advance the notion that the two-implant overdenture is the more appropriate starting point among a hierarchy of treatment options based on the science now considered to be valid. Ultimately, as health professionals, it is time to “raise the bar.” Acknowledging and understanding the biological and functional benefits of the two-implant overdenture is a necessary first step in this considerably important paradigm shift.

Table of Contents

Preface

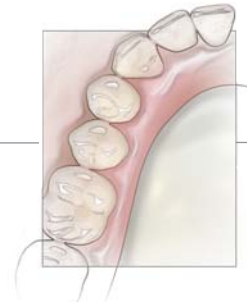
1 The State of Edentulism

CHAPTER



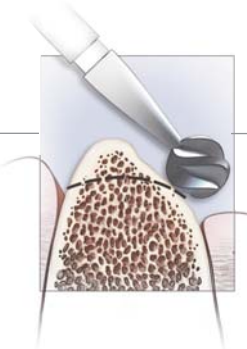
2 Treatment Planning for the Two-Implant Overdenture

CHAPTER



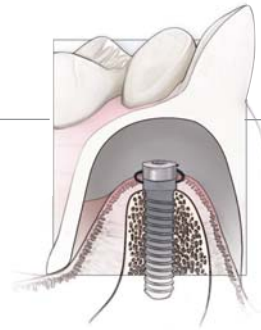
3 Surgical Principles

CHAPTER



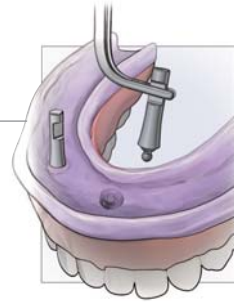4 Loading Protocols

CHAPTER



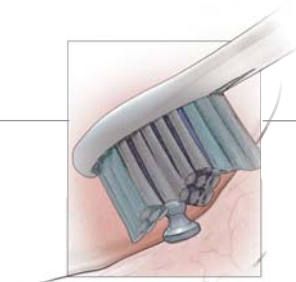
5 Prosthetic Guidelines

CHAPTER



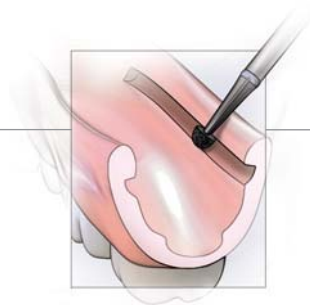6 Maintenance

CHAPTER

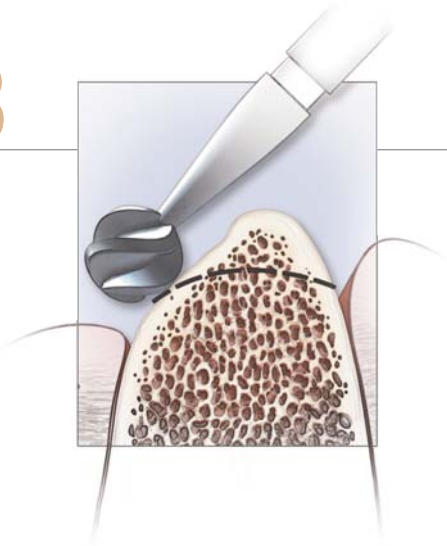


7 Future Considerations

CHAPTER



References



Surgical Principles

While exact implant position is critical for fixed prostheses, it is equally important for removable prostheses where improper placement may negatively affect tooth position, attachment mechanism, and flange extension. Prior to implant placement surgery, the clinician must determine the intended final position of the artificial tooth position and the form of the overdenture. Often, there is a tendency to consider implant placement first and artificial tooth position and overdenture form later.

Implant Selection

Successful treatment with the two-implant overdenture has been documented with multiple implant designs (eg, hexagonal, Morse taper, internal connection) and many implant systems. Clinicians may select implants for retention of the two-implant overdenture according to personal experience and preference with confidence that treatment success will not be determined by the selection made. This is due primarily to the anatomy and density of the bone in the anterior mandible.

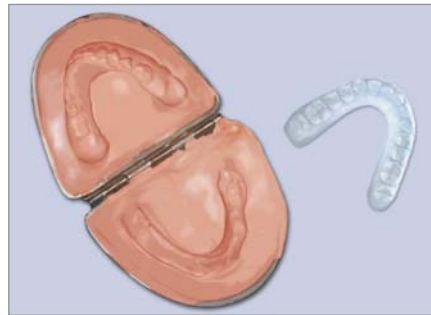
Surgical Considerations for the Two-Implant Overdenture

1. Final Prosthetic Tooth Form

To communicate prosthetic requirements to the surgeon, the final denture should be duplicated in clear acrylic resin as the surgical guide. As an alternative, the final denture can also be prepared (ie, with access windows or holes) to serve as the guide and later repaired (Figure 3-1).

Fabrication of surgical guide, either from the patient's existing denture or in the fabrication of a new two-implant overdenture, after final tooth position has been established or following the processing of a new denture.

3.1



2. Available Bone

The available bone for implant placement is dependent on the three-dimensional resorptive process (ie, anterior, inferior, lateral).

3. Final Restorative Design

Implant placement is restoration-specific, meaning the final position is as unique as each final restorative design. Fixed prostheses are different from removable designs, and the bar overdenture is vastly different from the unsplinted two-implant overdenture.

4. Number of Implants: Two

One way to significantly diminish the cost of implant treatment is simply to reduce the number of implants needed and to keep them unsplinted (eliminating the bar and its laboratory fees). Utilization of two implants has been demonstrated in numerous, long-term studies worldwide to be clinically successful, economically advantageous to the patient, and structurally sufficient to retain an overdenture. In the mandibular anterior region, a smaller number of implants will not adversely affect success rates, meaning fewer implants can be equally effective.^{33,34} Additionally, randomized controlled clinical trials have demonstrated that patients are equally satisfied with two implants retaining an overdenture as compared to multiple implants.³⁵ Therefore, there is consensus that two implants splinted or unsplinted should be considered the minimal objective for mandibular overdenture treatment.

Do not extrapolate guidelines for the mandibular two-implant overdenture to the maxillary arch.

5. Implant Position: Ideally Canine or Lateral Location

Implants in the anterior mandible should be placed in the canine or lateral positions. Implants positioned in this slightly more anterior position reduce the tendency for the denture to rotate around the fulcrum provided by the denture. The denture base may lift when the patient incises anteriorly if implants are placed too far distally.



NOTE: The unsplinted overdenture is not constrained by specific inter-implant space requirements, meaning no such measurements are necessary. Although not a standard procedure, when a bar (ie, splinted) two-implant overdenture is fabricated, an inter-implant distance of no more than 15 mm to 20 mm is needed to accommodate at least one clip and for metallurgic considerations.

6. Surgical Protocol: Ideally A One-Stage Procedure

Comparable clinical success rates have been reported with one-stage versus two-stage implant treatment, including the absence of significant differences in marginal bone resorption and the attainment of similar tissue health.³⁶⁻³⁸ This and other evidence-based literature is sufficient to support modification of the original two-stage surgical protocol to a one-stage nonsubmerged approach. In addition, one-stage treatment increases case acceptance, reduces postoperative discomfort, and allows use of early loading protocols. The selection of the loading protocol has a significant influence on the course of surgery as well as restorative treatment and must be preliminarily determined during treatment planning (see Chapter 5).

7. Attached Keratinized Tissue

The final healing abutments should be surrounded by a circumferential zone of attached tissue.

Indications for One-Stage Surgery

Although the one-stage approach is the desired treatment, it may only be determined at the time of surgery and may be altered accordingly.

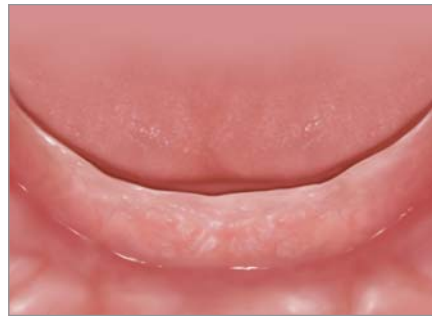- Simple and uncomplicated implant placement: When no auxiliary procedures (eg, hard and soft tissue grafting) are required.
- Adequate primary stability must be attained: Resistance of at least 30 Ncm or implant stability quotient of >60 can be achieved at the time of placement.

When the following conditions are NOT present, a two-stage surgical protocol is to be used.

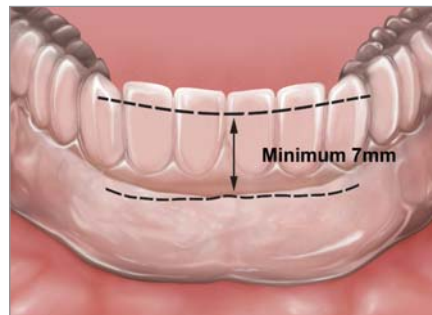Table 3-1. Influence of Surgical Approach on Restorative Protocol

A. One-stage implant placement	→ Denture	→ Early loading protocol
B. Two-stage implant placement	→ No denture	→ Conventional loading protocol

3.2 Clinical examination should include an evaluation of size and shape of the edentulous ridge (both buccal and lingual areas are critical), palpation (undercuts), and an assessment of remaining tissue types (keratinized vs. mucosa). Panoramic radiographs and/or CT scans are likewise recommended.



3.3 Prior to surgery, the surgical guide is inserted to permit evaluation of all necessary restorative space. A minimum of 7 mm of restorative space in an inferior-superior dimension is necessary.



Surgical Protocol for Implant Placement

1. Try-in the surgical guide to assess available restorative space and determine flap design (Figures 3-2 and 3-3).

The restorative space in the facial plane should be evaluated from the approximate position of the buccal bone to the inner aspect of the lingual denture base, not from bone to the incisal edge position. Space evaluation is most easily performed prior to reflection of the surgical flap. Contingent upon the type of overdenture abutment planned, the **minimum restorative space (ie, 7mm)** should then be verified (Figure 3-3). This space is necessary to accommodate the height of the abutments, the retentive elements, and an adequate thickness of acrylic without overcontouring the lingual or buccal flange.

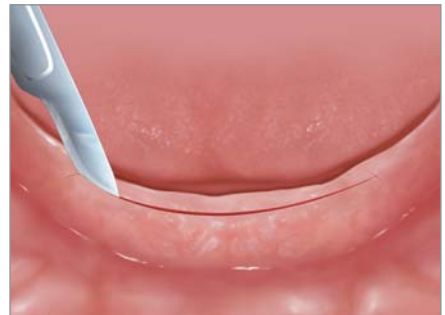2. Design the incision.

Incision design will depend on the overall prosthetic needs. Options include:

- A. **A traditional midcrestal incision** ending slightly distal to the canine position, followed by a full-thickness flap and buccal and lingual reflection to gain access that will allow final evaluation of the shape, size, and trajectory of the remaining bone (Figures 3-4 through 3-6). This is the technique of choice for optimal access and is indicated when **osseous recontouring is needed**.

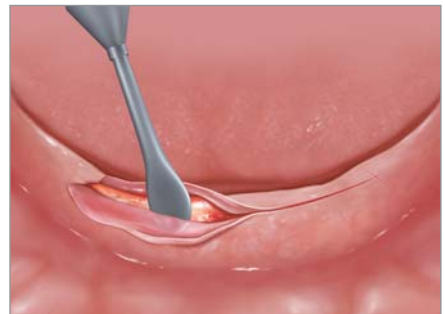A midcrestal incision is made, ending distally to the canine position (as dictated by surgical guide), often with two small vertical releasing incisions.

3.4



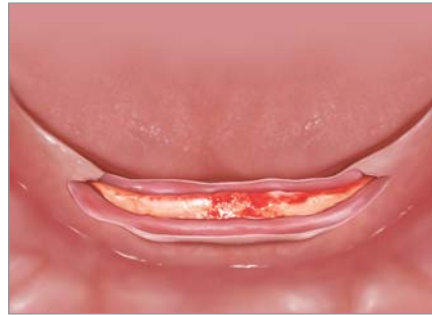A full-thickness flap is performed with buccal and lingual reflection.

3.5



Ideal surgical principles require flap reflection to be as conservative as possible while attaining ideal access to evaluate size, shape, and trajectory of the remaining bone.

3.6

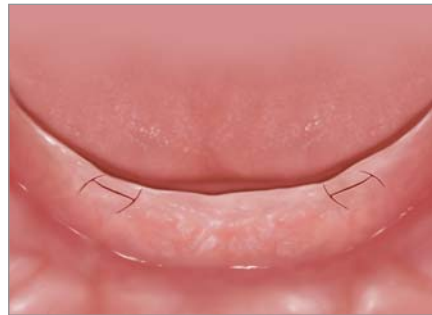

B. Modification of the traditional approach with a **midcrestal incisions** starting slightly distal to the canines but not crossing the midline (ie, two mini-flaps). This approach is indicated when **osseous recontouring is not needed** or in the case of an edentulous ridge with a wide flat shape (Figure 3-6a). Advantages include:

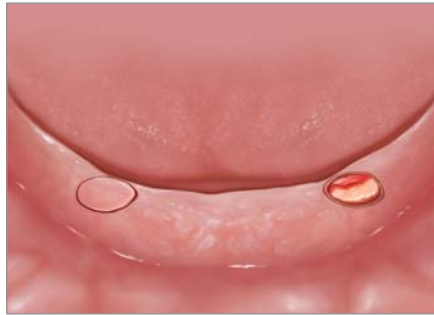
- Smaller flap with less resultant discomfort and swelling because muscle attachments are uninvolved;
- Smaller flap with less resultant bone loss; and
- Smaller area to reline (ie, sectional reline versus a full reline).

A modification of traditional approach. Two small mini-flaps, starting slightly distal to the canine position, but not crossing the midline, are utilized for a broad flat ridge when osseous recontouring is not needed.

3.6a



C. **The punch and flapless technique** through intact tissue is indicated for a broad, flat ridge when **osseous recontouring is not needed**, and an adequate zone of attached tissue is present (Figure 3-7). Of the three options, this is the most conservative approach in that it results in the least bone loss and smallest area to reline.

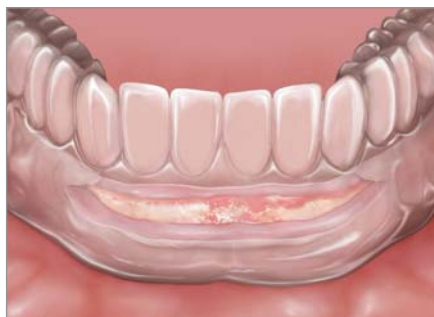

3.7 | *Depiction of an even more surgically conservative flapless or “punch” technique.*

3. Re-seat the surgical template.

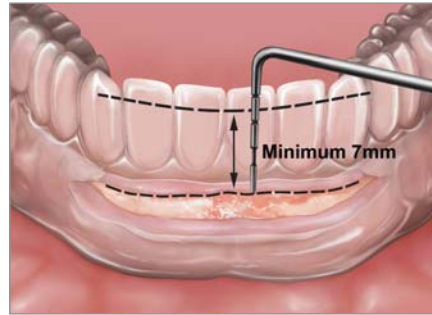
Using previously established records, the surgical guide is placed in position, taking care that the reflected flap does not impede proper seating of the guide (Figure 3-8). With the guide in position:

- A. **FACIAL PLANE:** Re-evaluate the inferior-superior dimension and modify space as needed (Figure 3-9). If additional restorative space is needed and it has been determined that it cannot be obtained prosthetically by increasing the vertical dimension of occlusion, recontour the residual ridge sufficiently to accommodate the overdenture components (Figures 3-10 through 3-13). It should be remembered that this strategy undermines the function of implant treatment to preserve bone and prevent additional resorption. The technique should be as conservative as possible while maintaining sufficient volume of bone for implant placement.

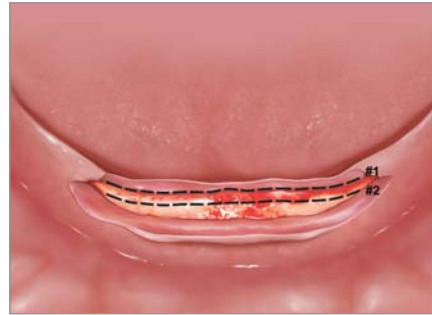


3.8 | *The surgical guide is resealed, taking care that the reflected flaps do not impede proper position. Excess relief on the tissue aspect of the surgical guide is expected.*

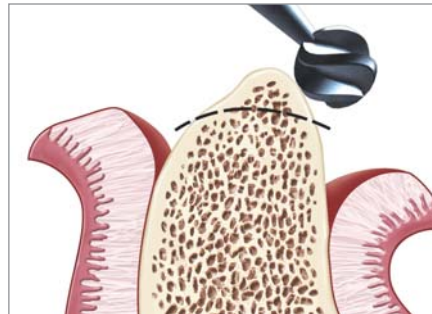
3.9
Once the surgical guide is in place, the restorative space is reevaluated to determine if osseous recontouring is indicated. A periodontal probe or calipers may aid in this process.

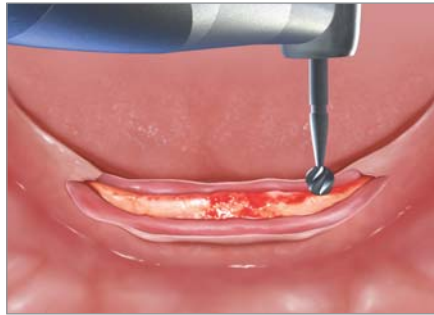

3.10
The surgical guide is removed. Position #1 illustrates current position of osseous crest. Position #2 illustrates the amount of bone that may need to be removed and reshaped during alveolectomy.

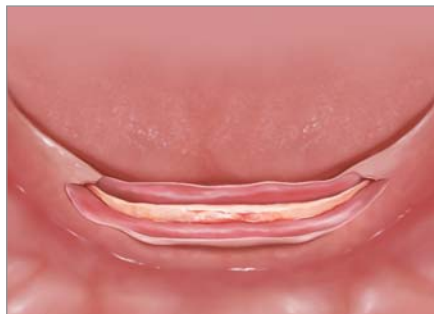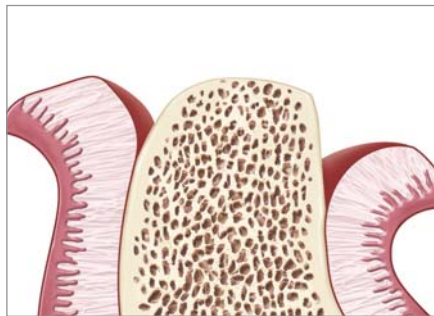


3.10a
Knife-edge ridges need to be reshaped and recontoured either with rotary instruments or rongeurs to permit adequate bone width for implant placement.





- 3.11** | Final osseous recontouring must result in a broad, wide, and flat ridge with buccal and lingual bone at approximately the same heights. If one side is higher, it can impinge on restorative space as a larger final abutment will be needed.
- 3.12** |



- 3.13** | Final desired surgical endpoint prior to implant placement. Note the flat osseous contour without any undercuts, concavities, or need for grafting.



NOTE: It is important that the osseous crest is flat to minimize the height of the overdenture abutment.

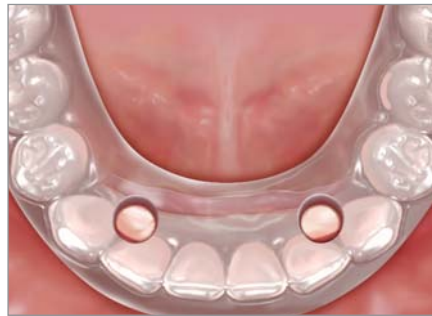

CAUTION: If the osseous crest is inclined, a higher abutment will be required, resulting in an undesirable reduction in overall restorative space.

- B. OCCLUSAL PLANE: Evaluate the buccolingual dimension. Implant position may be slightly more lingual as compared to a fixed prosthesis depending on how much ridge resorption has occurred. In the case of the minimally resorbed mandible, a slight lingual position is more ideal (Figure 3-14). When more extensive resorption is present, the implants could be placed “under” the denture teeth since there is a sufficient bulk of acrylic. To achieve a “layering concept” in the anterior-posterior dimension, implants should be positioned slightly more to the lingual and apical but with the top of the implant angled toward the buccal to minimize bulk lingually. This will provide sufficient space for overdenture abutment retentive elements, adequate thickness of acrylic, and a full-denture tooth that is modified minimally.
- C. SAGITTAL PLANE: Evaluate space in the sagittal plane. Implant position is prosthetically driven. Since the path of draw of the prosthesis is determined by the trajectory of the remaining bone, implants must be placed in this plane (Figure 3-15). If the trajectory of the bone is facial, the first implant must be as parallel as possible to the facial. The second implant should be parallel to the first. For an extreme trajectory or large facial undercuts, minor osteoplasty is indicated.

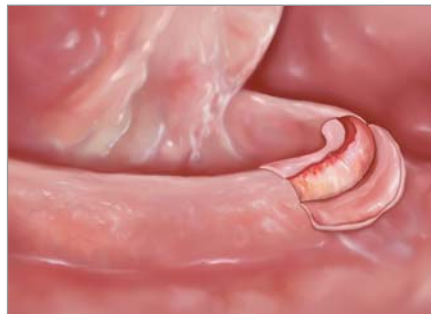In the case of the minimally resorbed mandible, implants need to be placed slightly more lingual to allow space for the overdenture abutment, the retentive element, acrylic, and a full-sized denture tooth.

3.14



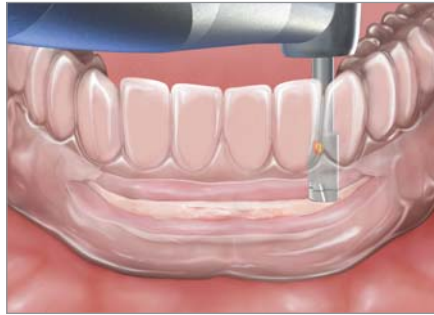
The trajectory of the remaining bone must be evaluated from a sagittal position. The first implant must be placed parallel to this trajectory to aid in the proper draw of the overdenture and to minimize unnecessary bulk of the denture base.

3.15

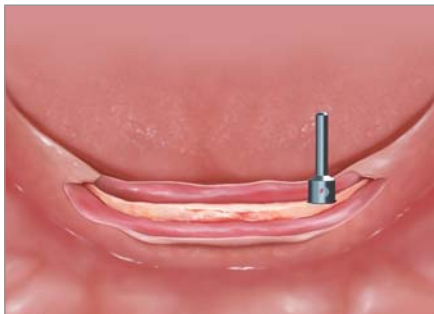
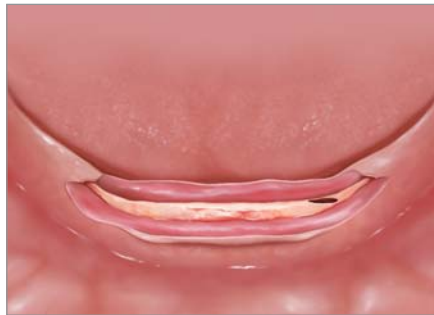
4. Create the osteotomy.

Osteotomy technique will be based on the implant manufacturer's recommendations (Figures 3-16 through 3-20).

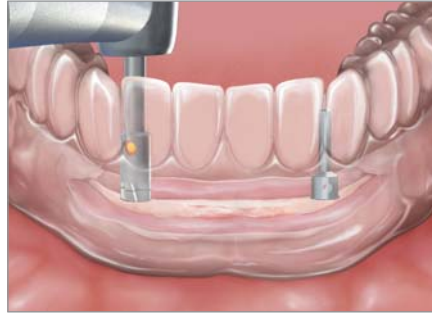

3.16 | Using the surgical guide to ensure appropriate positioning, the osteotomy sites are prepared in the canine regions.

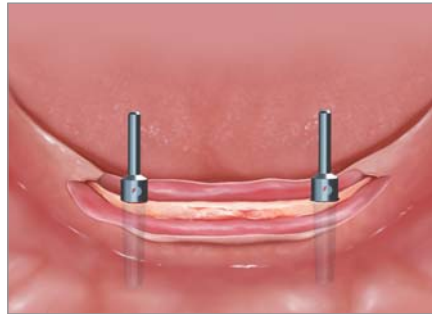

3.18 | A guide pin is inserted into the osteotomy site to ensure that the second implant is as parallel as possible to the first.

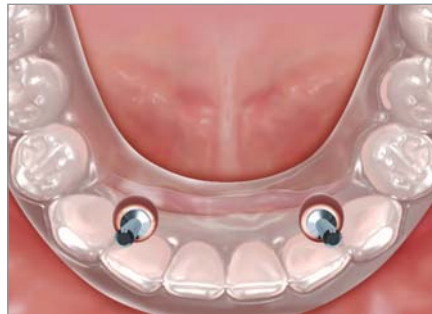The second osteotomy is completed using both the surgical guide and the direction rod to ensure appropriate position. **3.19**



The second guide pin is inserted to reevaluate implant parallelism. It is recommended that the implants be as parallel as possible to each other as well as to the trajectory of the remaining bone. This will allow greater choices in restorative components. **3.20**



The guide pins are then reevaluated via the surgical guide. The pins must exit the surgical guide lingual to the final facial tooth position. If this is not the case, an osteotomy exit angle must be altered. Angling the implants toward the buccal will often minimize bulk on the lingual aspect of the prosthesis. **3.21**

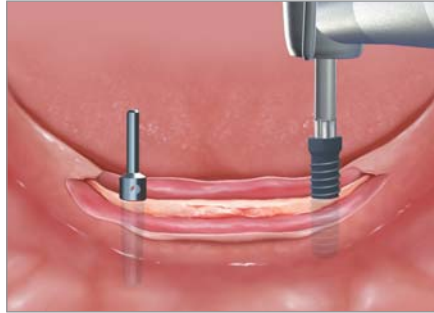

5. Place the implants as indicated by the surgical template.

Final placement of the implants follows the principles of ideal implant parallelism and maximum initial stabilization, and path of draw (Figures 3-19 and 3-22).



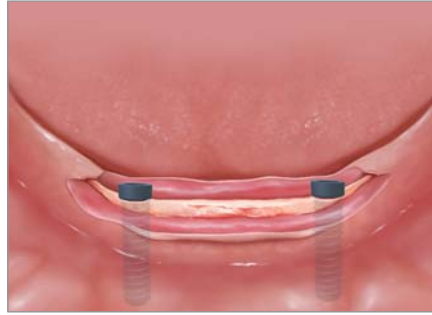
NOTE: Generally, studies indicate that failure to achieve ideal implant parallelism will result in higher maintenance needs for the unsplinted overdenture patient. Therefore, implant parallelism is of considerable importance from a prosthetic and aftercare perspective.



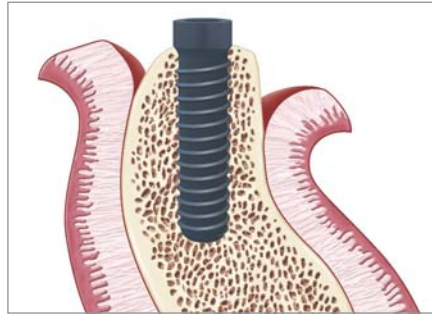
3.22 | *As dictated by the implant manufacturer, osteotomy sites are completed and the implants are placed, again, using the guide pins.*

According to the literature, two standard diameter implants at least 10 mm in length are generally sufficient to provide long-term retention and support for an overdenture prosthesis.^{39,40} Although the successful use of shorter implants has been reported,⁴¹ at this time there is generally a lack of available data supporting the use of shorter implants with newer surface topographies or other nanochemical enhancements as a routine procedure. Further research is needed in this area.

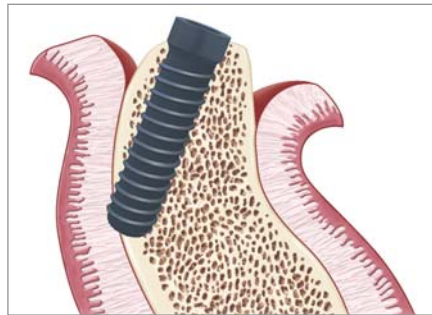
3.23 Under most conditions, supra-crestal placement should be considered the ideal surgical endpoint since aesthetics is not a factor. This position will simplify the final restorative protocol.



3.24 Proper angle for implant placement.



3.25 An improper angle for implant placement can perforate the lingual cortex and, in cases involving an unreflected lingual flap (ie, mini-flaps, flapless), can lead to significant surgical complications!



NOTE: It cannot be overemphasized how critical it is to avoid lingual perforation during implant placement—hemorrhage of the floor of the mouth is a potentially serious complication (Figures 3-24 and 3-25).⁴²

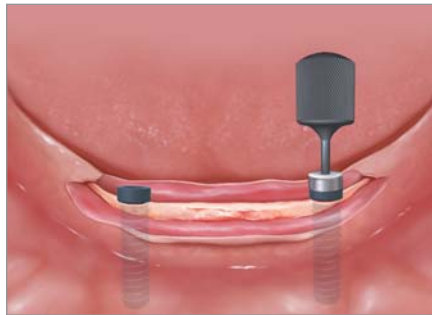Supracrestal placement should be considered the ideal surgical endpoint. Countersinking may be needed, however, for clearance for the prosthetic components at times. Generally, this can be avoided with proper planning (Figure 3-23).

6. Place healing abutments.

Since a one-stage protocol is the treatment of choice, the final healing abutment is placed at the time of surgery (Figure 3-26). Placement of the superior aspect of the healing abutment approximately 1 mm to 2 mm above the final flap position will allow for healing and maturation of the soft tissue. If a two-stage protocol is indicated, a surgical cover screw is placed until the second-stage surgery.



NOTE: Placement of the healing abutment at an excessive height (eg, 4 mm to 5 mm) above the final flap will lead to excessive adjustment of the denture base, resulting in reduced acrylic thickness and an increased risk of denture base fracture. In addition, excessive height in the healing abutment may increase the incidence of micromovement of the implants and makes relieving the denture base considerably more difficult.



3.26 | Healing abutments are then placed at proper height. The authors recommend no more than 1 mm to 2 mm of abutment height above the final proposed flap position.

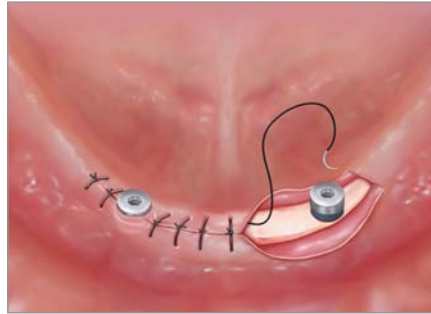
7. Suture to achieve final closure.

Interrupted sutures are sufficient for closure, but the final decision is at the discretion of the surgeon (Figures 3-27 and 3-28).

An important surgical objective is to have a circumferential zone of attached tissue surrounding the healing abutments. This is recommended for ease of hygiene, comfort, and overall generally more predictable long-term outcomes. To accomplish this goal, apically positioned flaps with periosteal sutures are an option, depending on overall tissue thickness).

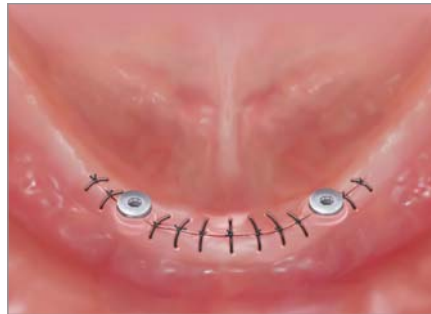The replaced surgical flap is closed and secured using a vertical mattress or interrupted suturing technique.

3.27



Final closure is achieved and represents the last step for one-stage surgical procedure (ie, uncomplicated implant placement). Note the low profile of the healing abutment. For large ridges, it is acceptable for the healing abutment to have a low profile after suturing. If the ridge is resorbed, longer abutments may be necessary to prevent tissue from overgrowing the abutments.

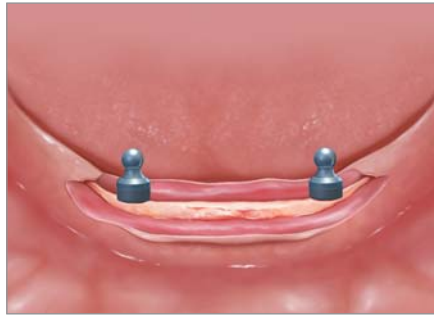3.28



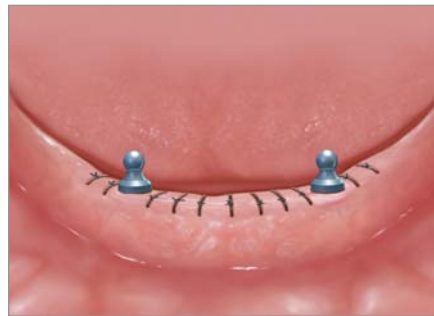Final Overdenture Abutment Versus Healing Abutment (Figures 3-29 and 3-30)

ADVANTAGES of placement of final abutment

- Use of less components reduces treatment cost to the patient;
- Restorative dentist not required to select an abutment; and
- Restorative dentist's need for implant instrumentation eliminated.



3.29 | *In lieu of a healing abutment, the final overdenture abutment may also be placed. Although this reduces the need for an additional component, final height is only estimated since it is not possible to approximate final tissue dimensions.*



3.30 | *Suturing technique is similar to when final healing abutments are used.*

DISADVANTAGES of placement of final abutment

- Approximating height of the final component becomes more difficult because tissue has not healed. Height may have to be changed later depending on tissue healing; and
- Difficulty of approximating height may increase the risk of micro-movement for the inexperienced practitioner.

Placement of a **final abutment** is generally easier in the advanced resorbed patient because more space is available and the exact height of the overdenture abutment is less important.

An understanding and proper execution of these surgical principles will significantly simplify the restorative aspect of two-implant overdenture treatment.

SUMMARY

- Prior to implant surgery, the clinician must first determine final tooth position and overdenture form and transfer this information to a surgical guide.
- Implant placement should be dictated by a balance between final tooth position (ie, via the surgical guide) and available bone, which should be considered three dimensionally.
- There is a consensus that two implants (ideally in the canine or lateral position) is the minimal implant standard of care in the edentulous anterior mandible to retain and support an overdenture.
- It is critical to avoid lingual perforation during implant placement. Hemorrhage of the floor of the mouth is a potentially serious complication!
- A simple, uncomplicated one-stage surgical protocol is considered the technique of choice with implants as parallel as possible to each other with the endpoint being supracrestal placement.



Joseph R. Carpentieri, DDS

Dr. Carpentieri received his Prosthodontic Certificate from Albert Einstein College of Medicine/Montefiore Medical Center in 1997 and is current a Fellow in the Department of Periodontology and Implant Dentistry at New York University College of Dentistry in New York, NY. He is also a Clinical Instructor in the Department of Graduate Prosthodontics at the Albert Einstein College of Medicine/Montefiore Medical Center in the Bronx, NY. He maintains a private practice in White Plains, NY, and is a major proponent in the implant overdenture as the first-choice standard of care.



Dennis P. Tarnow, DDS

As Professor and Chair of the Department of Periodontology and Implant Dentistry at the New York University College of Dentistry, Dr. Tarnow is one of dentistry's foremost educators and most well-recognized authorities in restorative care. He is a recipient of the University's prestigious Outstanding Teacher of the Year Award and numerous other honors for his dedication to his students and his expertise in implant dentistry. Dr. Tarnow has published in leading scientific dental journals for decades and has lectured worldwide on periodontal therapy and implant dentistry.